3} Postnatal

https://encrypted-tbn0.gstatic.com/images?q=tbn:ANd9GcR_cOmwTu22uyjxkfAlJxK8Hal-vI0ESiFmSw&s

18} Postpartum assessment (Fundal / lochia assessment)

Goal:

To monitor and evaluate the postpartum uterine involution and vaginal discharge (lochia) to ensure normal recovery, detect early signs of complications such as hemorrhage or infection, and promote maternal well-being.

Learning Objectives:

By the end of this procedure, students should be able to:

- Describe the normal postpartum changes in the uterus and vaginal discharge (lochia).
- Accurately assess fundal height and consistency.
- Identify types, amount, and progression of lochia.
- Recognize abnormal findings and understand their clinical implications.
- Document postpartum assessment findings appropriately.

Teaching Methods

- Interactive Lecture
- Demonstration
- Guided Hands-On Practice
- Case-Based Discussion
- Formative Assessment and Feedback.

Materials Needed

- Simulation manikins or models for fundal assessment.
- Simulated lochia pads with varying characteristics.
- Disposable gloves, measuring tape, bed linen, hand sanitizer.

- Assessment rubrics or checklists.

Introduction:

The postpartum period, also known as the puerperium and the "fourth trimester," refers to the time after giving birth when maternal physiologic changes related to pregnancy return to the non-pregnant state. Numerous disorders and complications may occur in the immediate postpartum period or after discharge from the birth facility.

Concept of Normal postpartum:

- It is the period following delivery of the baby and placenta to six –eight weeks postpartum.
- It is the period during it, the reproductive organs & maternal physiology returns towards the pre pregnancy state.
- It provides information about uterine involution by assessing the height, position of the uterus, and assess of lochia to detect any complications such as hemorrhage and infection.

Fundal assessment:

It is the tactile examination of the woman's abdomen (abdominal palpation) during the immediate postpartum period to assess the uterine involution.

Involution of the uterus:

Involution refers to the changes that occur on the reproductive organs particularly the uterus undergoes after childbirth as they return to their non-pregnant.

Importance of post-partum assessment:

1. To evaluate the involution process.
2. To determine the shape, position and consistency of the uterus.
3. To detect and locate any abnormalities (deviation from normal).

4. To prevent shock and hemorrhage.
5. To encourage muscle contraction of the uterus & reduce blood loss

Fundal level during postpartum:

- ☞ Immediately following delivery, the size of uterus as large grapefruit and can be palpated midway between the symphysis pubis and umbilicus,
- ☞ Within an hour, the fundus rises to the level above the umbilicus and should remain at this level for about 24 hours the uterus now weighs approximately 1000 gm.
- ☞ After 24 hours, the fundus begins to descend by approximately 1cm, or one fingerbreadth, per day, so that by the 10th day it is in the pelvic cavity and cannot be palpated abdominally.
- ☞ Within a week, the weight of the uterus decreases to about 500g; at 6 weeks, the uterus weight 60g.This is roughly the pre-pregnancy weight.

Uterine-Atony:

Failure of uterine muscles to contract adequately after delivery. That leading to post-par-tum hemorrhage. There are many causes of uterine atony such as prolonged labor, Retained placental tissue or placental disorders, such as an adherent placenta, placenta previa, and abruption placentae increase the risk of post-partum hemorrhage.

Lochia:

Lochia is normal vaginal discharge after birth, lochia containing blood, mucus, and uterine tissue. Lochia discharge typically continues for six to eight weeks after child-birth.

Types of lochia:

1-Lochia rubra (1-3 days): is the first red in color discharge, composed of blood, shreds of fetal membranes, decidua, vernix caseosa, lanugo

and membranes. It is red in color because of the large amount of blood it contains. It lasts 1to 4 days after birth, sometimes to7days.

2-Lochia Serosa (4-10 days): pinck, yellow discharge**.** It contains serous exudates, erythrocytes, leukocytes, cervical mucus and microorganisms.

3-Lochia Alba (or purulent)(11-17 days): creamy or white discharge**.**it contain leukocytes and mucus

A Tony:

Absence or lack of usual muscle tone.

Engorgement:

It is swelling of the breast resulting from increasing blood flow& presence of milk.

Assess the uterus for (location, position, and tone) of the fundus.

After the third stage of labor, assess the uterus:

- ✓ Every 15 minutes for the first hrs
- ✓ Every 30 minutes for the second hrs
- ✓ Every 4 hours for the next 22 hrs
- ✓ Every shift after the first 24 hrs

Before assessment

- ✓ Explain the procedure to the woman.
- ✓ Instruct the woman to void.
- ✓ Provide privacy.
- ✓ Lower the head and foot of the bed so that the woman is in a supine position and flat.

Technique

- ✓ Support the lower uterine segment by placing one hand just above the symphysis pubis
- ✓ Locate the fundus with the other hand using gentle downward pressure.

- ✓ Determine the tone of the fundus: Firm (contracted) or soft (boggy)

Assessment of Lochia

The amount of flow is determined by the amount of Lochia on a perineal pad after 1 hour.

Lochia is assessed as scant, light, moderate, or heavy

- ✓ Scant is less than 2.2cm on the pad.
- ✓ Light is less than 8.8cm on the pad.
- ✓ Moderate is less than 13.2 cm on the pad.
- ✓ Heavy is when the pad is saturated within one hour.

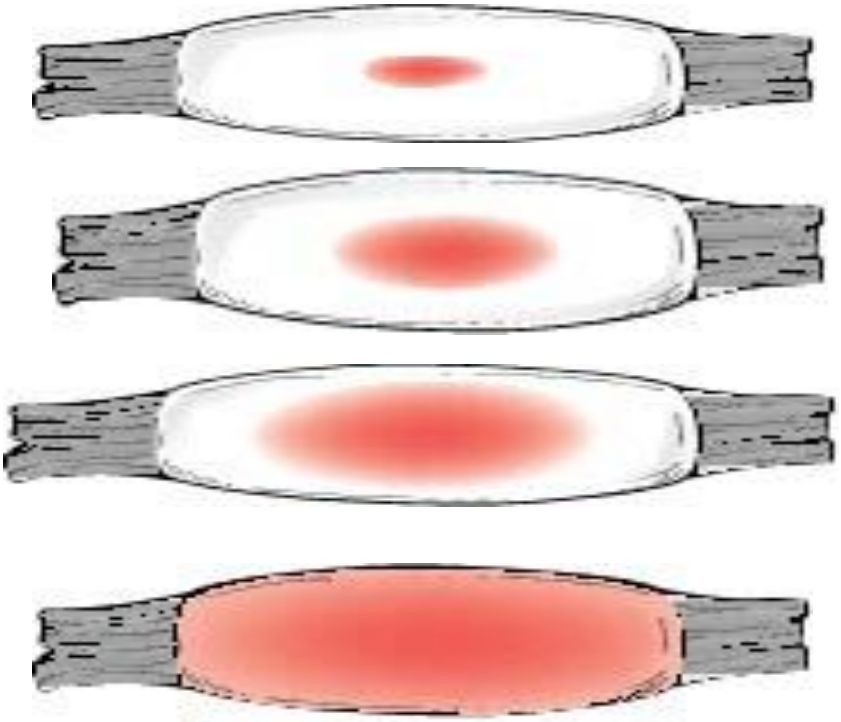

Heavy: Saturated pad

Assessment for Breast

- In the first **24 hours** postpartum, the breasts are soft and non-tender.
- On postpartum **day 2,** the breasts are slightly firm and non-tender.
- On postpartum **day 3**, the breasts are firm, tender and warm to touch due to breast engorgement.

The perineum

The assessment of the perineum for episiotomy and detection of hemorrhoid is done while the mother lying in **Sim's position**

Assess the perineum every shift using the acronym **R E E D A**-

(**R**edness, **E**dema, **E**cchymosis, **D**ischarge, **A**pproximation of edges).

Specific post-partum maternal assessment using (BUBBLE HE) acronym

acronym	Means	What to assess
B	Breast	Assess breast for, general appearance, size, shape, and consistency.
U	Uterus	Assess uterus for Condition ,level and position :
B	Bladder	Assess bladder function through asking mother about, pattern of urination and urinary output and observing signs of bladder distension, e.g.: (bulging of the bladder above symphysis pubis, and bladder discomfort).
B	Bowel	Assess passing of gases or stool and assess for hemorrhoids
L	Lochia	Assess lochia for amount, type, odor, color, and consistency.
E	Episiotomy	Assess episiotomy with the aid of (REEDA), method which includes:- R redness. E edema. Eecchyosis. D discharge. A approximation of sutures
H	Homan's sign	Performing Homan's sign technique for the mother to detect presence of any sign of D.V.T. Assess lower extremities for, size, shape, symmetry, varicosities, edema, tenderness, and signs of thrombophlebities, in the immediate postpartum period.

Equipment:

1. Disposable or sterile gloves.
2. Clean vaginal pad. 3- Rubber sheet. 4. Paper bag.

Assessing (Funds/Lochia) Guidelines

Nursing action	Rationale
1-Introduce yourself and explain the procedure.	- To reduce anxiety and elicited cooperation.
2- Ask the mother to empty her bladder (if she had not voided recently.)	- A distended bladder displaces the uterus.
3- Keep privacy.	
4- Wash hands.	-To decrease spread of microorganisms
4- Place the mother in a supine position with her knees slightly flexed. 5- Ensure she is comfortable.	- This relaxes the abdominal muscles and permits accurate location of the fundus.
6- Expose the woman's abdomen	
7- Wear clean gloves, and lower the perineal pads to observe lochia as the fundus is palpated. 	-Gloves are recommended any time there is possibility of coming into contact with body fluid.
8- Place the non-dominant hand above the	- This supports and

symphysis pubis.	anchors the lower uterine segment during palpation or massage of the fundus.
9- Gently palpate the fundus using the flat part of the fingers of the dominant hand.	- The larger surface provides more comfort
10- Begin palpation at the umbilicus and palpate gently until the fundus is located	
11-Measure by finger breadth how far the fundus from the umbilicus.	
12- Determine its size, position (at the middle or displaced to either sides) and consistency (normally contracted and firm or boggy and soft require massage).	- The fundus should be firm in midline and approximately at the level of the umbilicus
13- If the fundus is difficult to locate or is soft or boggy, keep the non-dominant hand above the symphysis pubis and massage the fundus with the dominant hand until the fundus is firm. 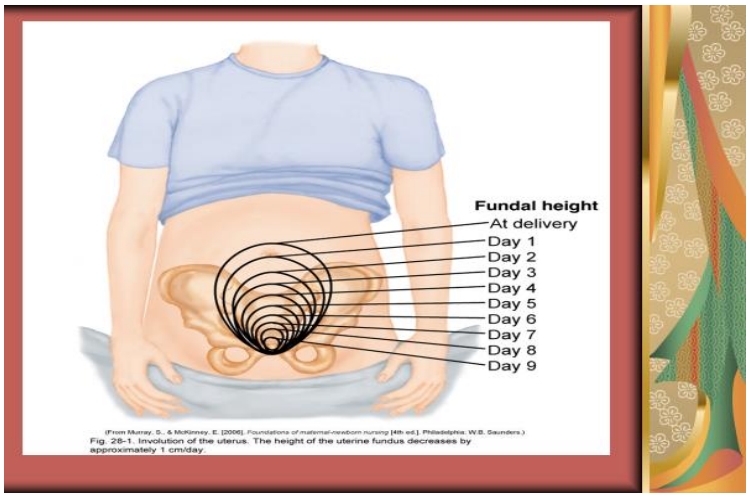	The non-dominant hand anchors the lower segment of the uterus and pre-vents trauma while the uterus is massaged. The uterus contracts in response to tac-tile stimulation; contraction is essential to control excessive bleeding.

14- Put new perineal pad after per-forming perineal care.	- To promote comfort.
15- Recover the abdomen, assisting the woman to a comfortable position.	
16- Discuss the findings with the woman.	
17- Document the consistency and location of the fundus. -Consistency is recorded as “fundus firm”, “firm with massage” or boggy Fundal height is recorded in finger breadth above or below the umbilicus. i.e., “fundus firm (Two finger breadth below umbilicus). As another example “fundus firm with light massage (two finger breadth above umbilicus).	-This promotes accurate communication and identifies deviations from the expected so that potential problems can be identified early.

Assessing The Fundus & Lochia

Nursing action	First		Sconde	
	Done	Not done	Done	Not done
1-Introduce yourself and explain the procedure.				
2- Ask the mother to empty her bladder (if she had not voided recently.)				
3- Keep privacy.				
4- Wash hands.				
5- Place the mother in a supine position with her knees slightly flexed. Ensure she is comfortable.				
6- Expose the woman's abdomen				
7- Wear clean gloves, and lower the perineal pads to observe lochia as the fundus is palpated.				
8- Place the non-dominant hand above the symphysis pubis.				
9- Gently palpate the fundus using the flat part of the fingers of the dominant hand.				
10- Begin palpation at the umbilicus and palpate gently until the fundus is located.				
11-Measure by finger breadth how far the fundus from the umbilicus.				
12- Determine its size, position (at the middle or displaced to either sides) and				

consistency (normally contracted and firm or boggy and soft require massage).				
13- If the fundus is difficult to locate or is soft or boggy, keep the non-dominant hand above the symphysis pubis and massage the fundus with the dominant hand until the fundus is firm.				
14- Put new perineal pad after performing perineal care.				
15- Recover the abdomen, assisting the woman to a comfortable position.				
16- Discuss the findings with the woman.				
17- Document the consistency and location of the fundus. -Consistency is recorded as "fundus firm", "firm with massage" or boggy Fundal height is recorded in finger breadth above or below the umbilicus.				
Score:				
Date:				

Student name: instructor signature: